

POLIO CHILD RELIEF MUMBAI

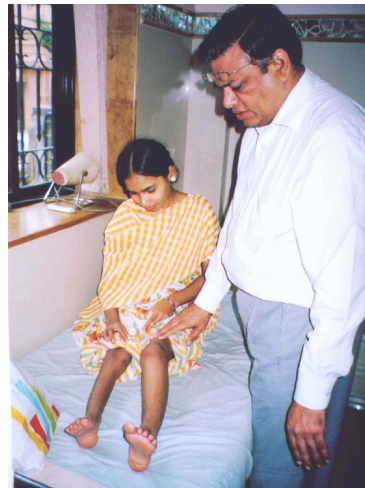103-104 Sagar Centre, 76 J. P. Road, Andheri West, Mumbai 400 058 INDIA
☎ : 26775796 / 26775499 / 26775797 / Dir: 9820250154 ● Fax: 0091-22-26775706
Email: pcr_mumbai@hotmail.com ● Web.: www.familycare.org/network/i16.htm

Mumbai, December 2008

December 2008 Project-Update



1-a) Aditya Ganpatil, who completed the treatment. Here with his father Ramesh(r) & Bandu (l) after last operation, recuperating at home.

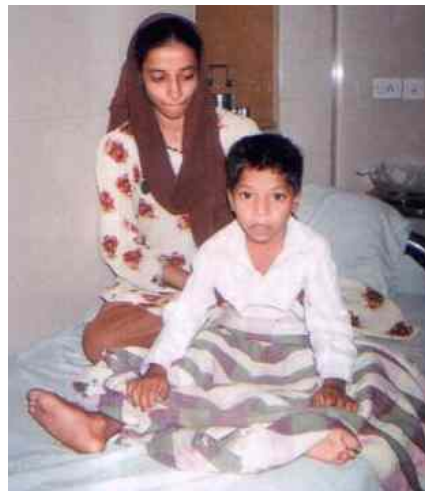

2-a) Jamila Banoo. Dr. Desai at the time of examining Jamila, giving the diagnosis for limb-lengthening surgery and treatment.

We hope and wish for her to still take up the treatment at a later time.

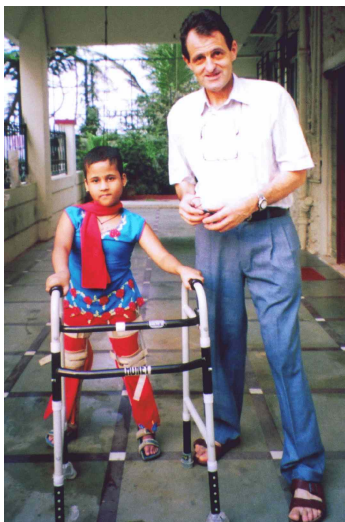

2-b) Deaf Muskan with her father Phiroj.

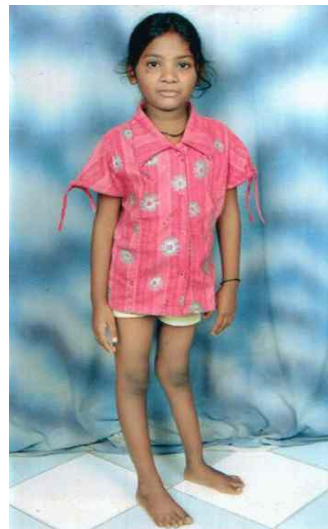

2-a) Soheli Kureshi. Soheli with his mother at the hospital in spring 2008. He completed the treatment and presently resides at his native place.

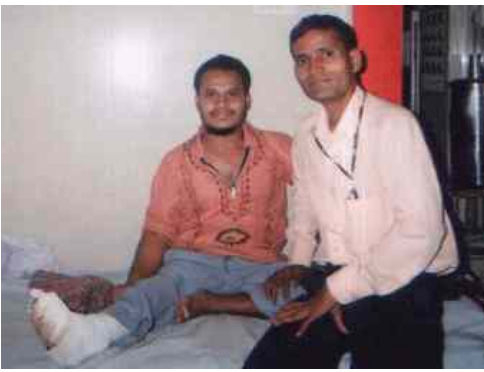A final check-up is to be carried out to determine if he needs any further medical assistance.



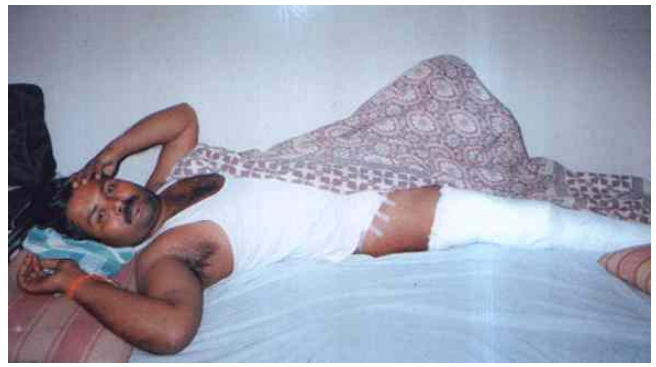2-c) Tejal Rana. Tejal visiting our Center after having completed her treatment at the end of the year 2007. PCR - Mumbai Project Manager Josef is happy with her progress, after five long years of treatment.



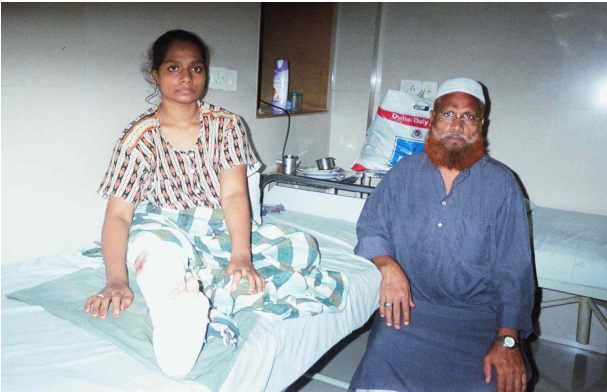3-a, 4-a) Aarti Dharoliya. In August 2008 we added this new patient, a young girl of a needy family, to the GSM Budget plan 07/08. She is presently in treatment, the progress has so far been good.



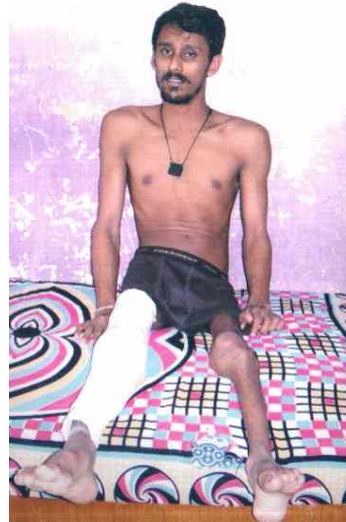4-b) Najir, who came to us first in 1998 for limb-lengthening is undergoing two phases of follow-up treatment with corr. surgeries.



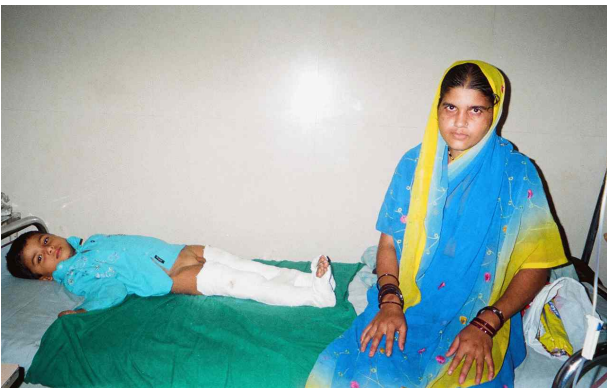4-c) Raju Belder has about 2/3 of his treatment completed and is waiting for sponsorship to complete the rest of his treatment.



4-d) Rijwana, with her father at the hospital of Dr. Desai, right after the 1st surgery. Her treatment is difficult & her family is very appreciative.

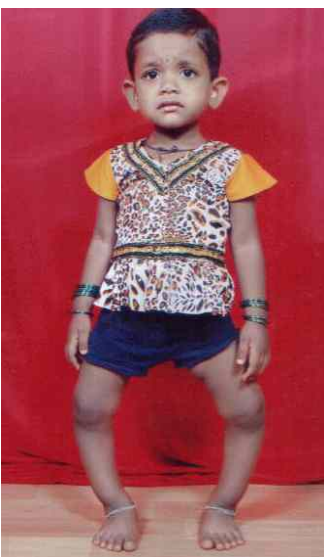

4-e) Firoj Shaikh, a brave young man with a positive outlook in life! He has completed half of his treatment, is presently undergoing physiotherapy and waiting for sponsorship to finish his treatment.

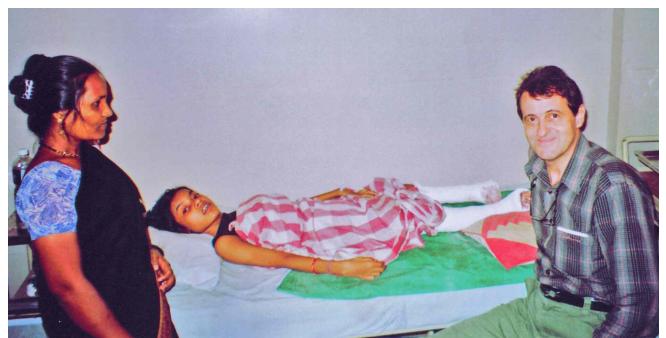


5-a) Layak Kureshi with his mother at the Shraddha hospital of Dr. Desai recuperating after a very recent surgery, his 1st stage treatment.

5-b) Reshma Tambe is a Polio patient with the typical deformities. She has good chances to be able to walk quite normal in the future. She needs 4 surgeries on her right side and one on the left. She may afterwards require a brace or caliper to help her gain the desired mobility.



5-c) Dipti Kamble. She suffers from deformities due to 'Rickets' and needs corr. surgery in three stages and a good amount of physiotherapy. This little girl will be getting treatment in early 2009, her family has to send her to Mumbai from the rural part of Maharashtra. Details of her medical checkup will be available later.



6-a) PCR-Mumbai Project Manager Josef with patient Amrapali G. More and her mother on the left. This girl of a very poor family completed half of her treatment in the first half of 2008.